

2026

Presence of second mesiobuccal canal of permanent maxillary first molars is related to the existence of multiple roots in permanent maxillary first premolars: A cone-beam computed tomographic study in a Taiwanese population

Zi-Jun Dai

Yi-Jie Chen

Hsin-Jui Liou

Tien-Hung Hsieh

Yu-Chiao Wu

Follow this and additional works at: <https://jds.ads.org.tw/journal>

Recommended Citation

Dai, Zi-Jun; Chen, Yi-Jie; Liou, Hsin-Jui; Hsieh, Tien-Hung; and Wu, Yu-Chiao (2026) "Presence of second mesiobuccal canal of permanent maxillary first molars is related to the existence of multiple roots in permanent maxillary first premolars: A cone-beam computed tomographic study in a Taiwanese population," *Journal of Dental Sciences*: Vol. 21: Iss. 2, Article 10.

Available at: <https://jds.ads.org.tw/journal/vol21/iss2/10>

This Original Article is brought to you for free and open access by Journal of Dental Sciences. It has been accepted for inclusion in Journal of Dental Sciences by an authorized editor of Journal of Dental Sciences. For more information, please contact cpchiang@ntu.edu.tw.



Available online at <https://jds.ads.org.tw/journal/>

Digital Commons

journal homepage: <https://jds.ads.org.tw/journal/>



Original Article

Presence of second mesiobuccal canal of permanent maxillary first molars is related to the existence of multiple roots in permanent maxillary first premolars: A cone-beam computed tomographic study in a Taiwanese population

Zi-Jun Dai ^a, Yi-Jie Chen ^a, Hsin-Jui Liou ^a, Tien-Hung Hsieh ^{a,b},
Yi-Chen Chung ^a, Che-Yuan Lin ^a, Ying-Wu Chen ^c,
Ren-Yeong Huang ^c, Yi-Shing Shieh ^{a,d}, Yu-Chiao Wu ^{a*}

^a Department of Operative Dentistry and Endodontics, College of Oral Medicine, Tri-Service General Hospital and National Defense Medical University, Taipei, Taiwan

^b Division of Dentistry, Tri-Service General Hospital Songshan Branch, Taipei, Taiwan

^c Department of Periodontology, College of Oral Medicine, Tri-Service General Hospital and National Defense Medical University, Taipei, Taiwan

^d Department and Graduate Institute of Biochemistry, National Defense Medical University, Taipei, Taiwan

Received 8 October 2025; Final revision received 23 October 2025

Available online 1 April 2026

KEYWORDS

Maxillary first premolar;
Maxillary first molar;
Multiple roots;
MB2;
CBCT

Abstract *Background/purpose:* Understanding root and canal morphology is critical for successful endodontic treatment. Detecting predictors of a second mesiobuccal (MB2) canal in permanent maxillary first molars (PMFMs) may improve diagnostic accuracy. This study examined the relationship between root number of permanent maxillary first premolars (PMFPs) and MB2 occurrence in PMFMs in a Taiwanese population.

Materials and methods: CBCT scans from 645 patients were reviewed, and 188 met the inclusion criteria, yielding 752 teeth (376 PMFPs, 376 PMFMs). Root number and canal morphology were classified using Vertucci's system. MB2 prevalence and bilateral symmetry were assessed.

* Corresponding author. Department of Operative Dentistry and Endodontics, College of Oral Medicine, Tri-Service General Hospital and National Defense Medical University, Room 5318, No. 161, Sec. 6, Minquan E. Rd., Neihu Dis., Taipei 114201, Taiwan.

E-mail address: joewuendo@mail.ndmctsgh.edu.tw (Y.-C. Wu).

<https://doi.org/10.1016/j.jds.2025.10.029>

1991-7902/© 2026 Association for Dental Sciences of the Republic of China. Publishing services by Digital Commons. This is an open access article under the CC BY-NC-ND license (<http://creativecommons.org/licenses/by-nc-nd/4.0/>).

Associations between PMFP root number and MB2 occurrence were analyzed with chi-square tests and multivariable logistic regression adjusted for sex, age, and side.

Results: Among PMFPs, 60.9 % had one root, 37.5 % had two roots, and 1.6 % had three roots. In single-rooted PMFPs, the most common configurations were Types I, III, IV, and II. In PMFMs, the mesiobuccal root most frequently showed Type I (42.0 %), followed by Type IV (30.8 %) and Type II (23.6 %). Males had a higher prevalence of multi-rooted PMFPs and MB2 canals than females. Logistic regression revealed that multiple-rooted PMFPs were independently associated with MB2 occurrence in PMFMs, with an adjusted odds ratio of 2.081 ($P < 0.001$). Bilateral symmetry was high in both PMFP root number (81.4 %) and MB2 presence (85.1 %).

Conclusion: Multiple-rooted PMFPs were strongly correlated with MB2 occurrence in PMFMs. PMFP morphology may serve as a predictive indicator for MB2 detection, enhancing diagnosis and treatment planning while no CBCT usage.

© 2026 Association for Dental Sciences of the Republic of China. Publishing services by Digital Commons. This is an open access article under the CC BY-NC-ND license (<http://creativecommons.org/licenses/by-nc-nd/4.0/>).

Introduction

The success of root canal therapy largely relies on thorough chemomechanical debridement and proper obturation of the canal system.¹ These steps are closely dependent on an in-depth understanding of the root and root canal anatomy. Recognizing potential variations, such as additional canals, accessory branches, apical deltas, or atypical root structures, enhances a clinician's ability to locate, shape, and disinfect the canal system during treatment.¹ In contrast, inadequate awareness of these anatomical complexities can result in missed canals, insufficient cleaning, or sub-optimal obturation, which are leading causes of persistent periapical disease and treatment failure.^{2,3} The introduction of advanced diagnostic technologies, particularly cone-beam computed tomography (CBCT), has highlighted the importance of three-dimensional imaging in accurately identifying canal morphology and supporting more precise treatment planning.⁴ Ongoing research and continuous training in root canal anatomy are therefore essential for improving clinical outcomes and ensuring predictable success in modern endodontic care.

Permanent maxillary first molars (PMFMs) are among one of the most frequently studied teeth because of the wide variability in the prevalence of a second mesiobuccal canal (MB2).⁵ A global CBCT-based study reported an overall MB2 incidence of 73.8 %, with prevalence ranging from highest 97.6 % in Belgium to 48.0 % in Venezuela.⁶ Ethnic differences were evident, and studies in Taiwanese populations have shown frequencies between 45.9 % and 74.0 %.^{7,8} Since MB2 occurs in just more than half of PMFMs in Taiwan, the likelihood of encountering it during treatment is comparable to the probability of flipping a coin.⁹ Therefore, identifying predictive factors is valuable to help clinicians anticipate MB2 presence and improve treatment planning and execution.

Compared with permanent maxillary first molars (PMFMs), fewer investigations have focused on the root and canal morphology of permanent maxillary first premolars (PMFPs).⁵ The reasons for this disparity are uncertain but may relate to the greater clinical challenges posed by PMFMs compared with PMFPs. A CBCT study conducted in a Chinese population reported that 66 % of

PMFPs had a single root, 33 % presented with two roots, and only 1 % displayed three roots.¹⁰

Identifying multiple roots is generally easier on periapical radiographs than detecting complex canals within a single root. Therefore, the present study aimed to examine the relationship between the root number of PMFPs (one root vs. multiple roots) and the presence of the MB2 in PMFMs in a Taiwanese population. The working hypothesis was that PMFPs with multiple roots would be correlated with a higher prevalence of MB2 in PMFMs. In addition, the study evaluated the root canal morphology of PMFPs and the mesiobuccal root of PMFMs according to Vertucci's classification, addressing the lack of such data in Taiwanese cohorts. Finally, the bilateral symmetry of PMFP root number and the presence or absence of MB2 in PMFMs was assessed.

Materials and methods

Database concealment, retrieving, and image attainment

All CBCT images analyzed in this study were obtained from a secure, encrypted database. The scans were stored in Digital Imaging and Communications in Medicine (DICOM) format and originated from patients treated in the Department of Dentistry at Tri-Service General Hospital, Taipei, Taiwan, between January and December 2024. These images were not initially collected for research purposes. During data handling, two authors anonymized all patient information, including names, record numbers, and phone numbers, by substituting them with serial codes. Ethical approval for this project was granted by the Institutional Review Board of Tri-Service General Hospital, Taipei, Taiwan (approval no. C202505122).

To ensure diagnostic accuracy while following the "as low as reasonably achievable" (ALARA) principle, scans were performed by three certified radiologists using a CBCT unit (Planmeca ProMax 3D ProFace, Helsinki, Finland). The machine operated at 80 kVp with a tube current of 15 mA and automatic exposure adjustments based on the target region, with each full-arch scan lasting about 12 s. Images were acquired at a voxel resolution of 0.15 mm.

Inclusion criteria required:

1. Bilateral presence of PMFPs, permanent maxillary second premolars (PMSPs), and PMFMs with fully developed roots.
2. No evidence of prior root canal therapy or radiopaque canal filling.
3. Absence of coronal restorations or post-and-core.
4. No large metallic restorations that could distort CBCT interpretation.
5. No radiographic signs of root resorption or periapical disease.
6. No history of root amputation or hemisection.
7. Clear, high-quality CBCT images in which canal orifices and root canal patterns could be reliably identified.

All scans (1920 × 1080 pixels) were reoriented so that the maxilla appeared bilaterally symmetrical, with the occlusal plane aligned parallel to the ground in both frontal and sagittal views.

Calibration on examiner reliability

Two examiners individually assessed the CBCT images, and any inconsistencies in elucidation were determined via discussion with corresponding author until agreement was accomplished. Intra- and inter-examiner calibration for nominal variables was managed to evaluate data trustworthiness, based on the morphological diagnosis of 50 randomly chosen CBCT images. Prior to resolving disagreements among the examiners, Kappa analysis was performed.¹¹ The kappa statistic values for nominal variables were 0.963 and 0.924 for intra- and inter-observer agreement, respectively (data not shown).

Sample size calculation and power analysis

To determine the appropriate sample size, a preliminary analysis was conducted using data assessed independently by two interpreters, who reviewed 50 cases. The aim was to estimate the minimum number of teeth required to detect a statistically significant difference between one-rooted and multi-rooted PMFPs with sufficient statistical power. According to the initial findings, 55.93 % of PMFMs exhibited a second mesiobuccal (MB2) canal in the one-rooted PMFP group, compared to 73.17 % in the multi-rooted PMFP group. Assuming an enrolment ratio of 0.69 between the groups, the calculation was carried out using a two-sided test with a significance level (α) of 0.05 and a statistical power of 80 % ($\beta = 0.20$). Based on these assumptions, the required total sample size was estimated to be 250 teeth (125 participants). This calculation ensures sufficient sensitivity to detect the anticipated difference, thereby reducing the likelihood of both Type I and Type II errors and strengthening the robustness of the study findings.

Root and root canal evaluation and classification

All eligible PMFP and PMFM images were analyzed using OsiriX Lite software (Pixmeo SARL, Bernex, Switzerland). Serial cross-sectional slices were examined from the

cemento-enamel junction (CEJ) to the root apex to assess root and canal morphology. For PMFPs, the number of roots and canal configurations were classified according to Vertucci's system. For PMFMs, the mesiobuccal roots were specifically assessed for the presence or absence of a second mesiobuccal canal (MB2). Cross-sectional images from the CEJ to the apex were evaluated, and canal systems were categorised as either "without MB2" or "with MB2," followed by classification using Vertucci's criteria.

1. Without MB2: A single canal located in the mesiobuccal root of the PMFM (Fig. 1A).
2. With MB2: More than one canal identified within the mesiobuccal root of the PMFM on CBCT slices and distribution of Vertucci's classification (Fig. 1B).
3. The symmetry of PMFPs' root number and PMFMs' MB canal category (without or with MB2) was also recorded (Fig. 1C).

Statistical analysis

Descriptive statistics were presented as means with standard deviations, frequencies, or percentages, depending on the type of variable, and calculated at either the patient or tooth level. The chi-square test was applied to assess differences in categorical variables, including sex (female vs. male), age (<50 years vs. ≥50 years), side (right vs. left), root number (one vs. multiple) of PMFPs, and PMFMs without or with an MB2 canal.¹² To evaluate the independent relationship between the root number of PMFPs and the presence of MB2 in PMFMs, a multivariable logistic regression was performed. The model was adjusted for potential confounders such as sex, age, and side. All statistical procedures were carried out using SPSS for Mac (version 31.0; SPSS Inc., Chicago, IL, USA). Statistical significance was set at a *P*-value <0.05.

Results

Study population and tooth characteristics

We initially screened CBCT scans from 645 patients, of which 188 met the inclusion criteria. This final sample consisted of 98 females (52 %) and 90 males (48 %), with ages ranging from 20 to 83 years (mean age: 43.9 ± 15.2 years). In total, 752 teeth were evaluated, including 376 PMFPs and 376 PMFMs (Table S1).

Analysis of prevalence and distribution across variables

In the PMFPs, males showed a significantly higher prevalence of multiple roots (46.1 %) compared with females (32.7 %). No significant differences were observed across age groups or between the right and left sides. A similar pattern was noted in the MB root of PMFMs, where males had a higher proportion with MB2 canals (54.3 %) than females (52.6 %), without significant variation by age or tooth side (Table 1). Regarding the main objective of this study, the presence of multiple roots in PMFPs was significantly

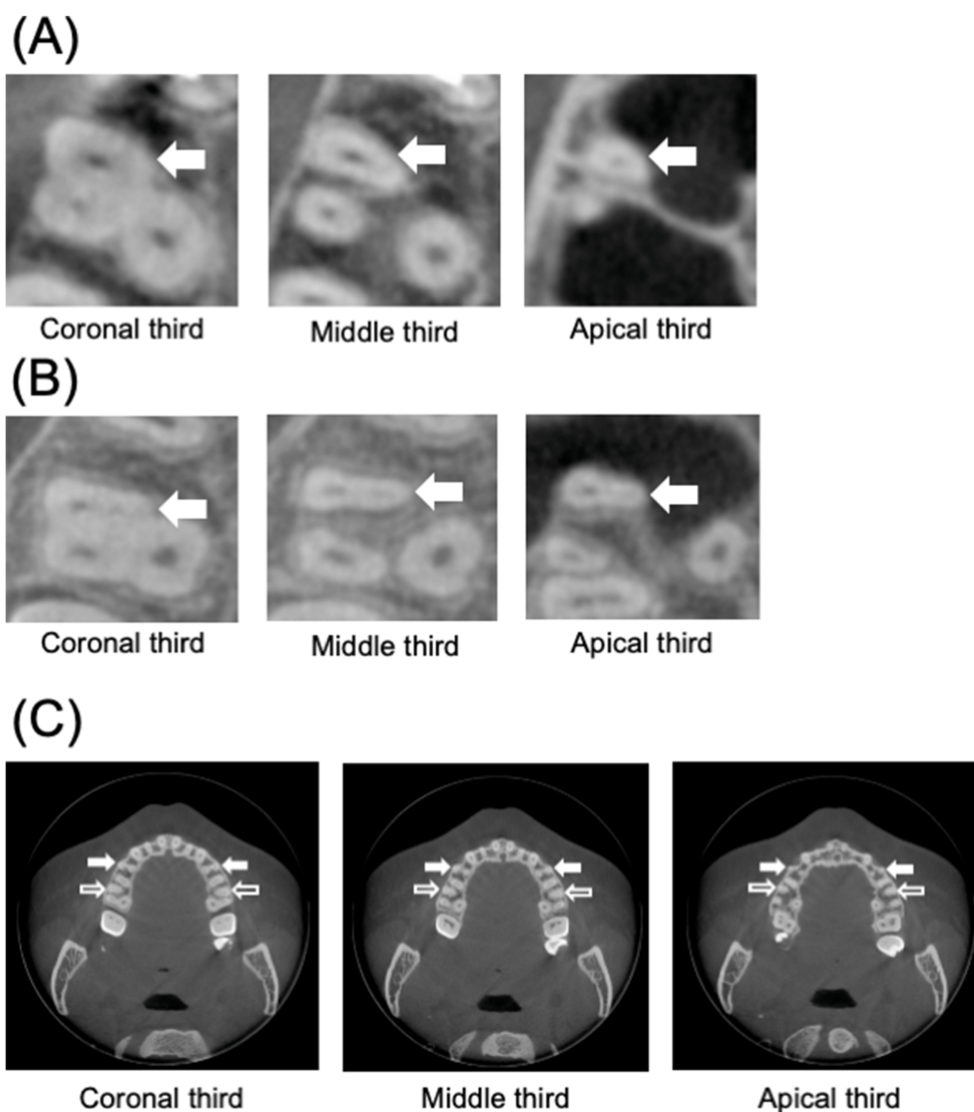


Figure 1 Representative images of without and with second mesiobuccal canal (MB2) in permanent maxillary first molars (PMFMs) and the symmetry of root number of permanent maxillary first premolars (PMFPs) and MB2 in PMFMs. (A) Without MB2 in PMFM. (B) With MB2 in PMFM. (C) The symmetry of PMFPs had two roots were indicated with white solid arrows, whereas black open arrows represent MB root of PMFMs had two canals.

correlated with a higher frequency of MB2 canals in PMFMs ($P < 0.001$) (Fig. 2). After adjusting for potential confounders through multivariable logistic regression, multiple-rooted PMFPs remained independently associated with MB2 occurrence in PMFMs, with an adjusted odds ratio of 2.081 ($P < 0.001$) compared with single-rooted PMFPs. Detailed findings are presented in Table 2.

Vertucci's classification of PMFPs' and PMFM's MB root canal configurations

The canal configurations of PMFPs and PMFMs were evaluated according to Vertucci's classification. Among PMFPs, 60.9 % had one root, 37.5 % had two roots, and 1.6 % had three roots. In single-rooted PMFPs, the most common configuration was Type I (14.6 %), followed by Type III (14.3 %), Type IV (13.6 %), and Type II (10.4 %). For the MB

root of PMFMs, Type I was observed in 42.0 %, followed by Type IV (30.8 %) and Type II (23.6 %) (Table 3).

Symmetry of PMFPs and PMFMs

To evaluate symmetry in PMFP root numbers and the presence of MB2 canals in PMFMs, we analyzed the relationship between contralateral PMFP root counts and MB2 occurrence in PMFMs. A high degree of symmetry was noted, with 81.4 % of PMFPs showing identical root numbers bilaterally and 85.1 % of PMFMs exhibiting symmetrical MB2 canal presence (Table 4).

Discussion

This CBCT-based investigation explored the relationship between root number in PMFPs and the occurrence of a MB2

Table 1 The prevalence and distribution of PMFP root number category and without/with MB2 in PMFPs were analyzed according to sex, age, and side.

	PMFPs, n (%)		Total	P-value	PMFPs, n (%)		Total	P-value
	One root	Multiple roots			Without MB2	With MB2		
Sex								
Female	132 (67.3)	64 (32.7)	196 (100)	<0.008**	93 (47.4)	103 (52.6)	196 (100)	0.026*
Male	97 (53.9)	83 (46.1)	180 (100)		65 (36.1)	115 (63.9)	180 (100)	
Age								
<50 years	131 (58.5)	93 (41.5)	224 (100)	0.243	101 (45.1)	123 (54.9)	224 (100)	0.143
≥50 years	98 (64.5)	54 (35.5)	152 (100)		57 (37.5)	95 (62.5)	152 (100)	
Side								
Right	112 (59.6)	76 (40.4)	188 (100)	0.597	84 (44.7)	104 (55.3)	188 (100)	0.296
Left	117 (62.2)	71 (37.8)	188 (100)		74 (39.4)	114 (60.6)	188 (100)	
Total	229 (60.9)	147 (39.1)	376 (100)		158 (42.0)	218 (58.0)	376 (100)	

PMFPs, permanent maxillary first premolars; PMFPs, permanent maxillary first molars; SD, standard deviation; n, tooth number. Data were analyzed using chi-square test. The level of statistical significance was set at $P < 0.05^*$, $P < 0.05^*$, $P < 0.01^{**}$, $P < 0.001^{***}$.

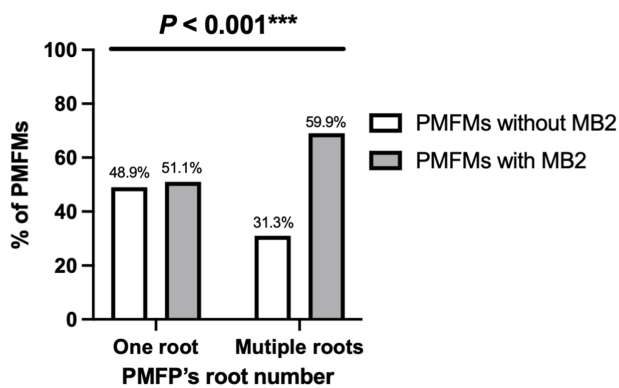


Figure 2 The presence of multiple roots in permanent maxillary first premolars (PMFPs) significantly increased the prevalence of second mesiobuccal canal (MB2) in permanent maxillary first molars (PMFPs) ($P < 0.05$).

canal in adjacent PMFPs within a Taiwanese population. The findings confirmed our initial hypothesis: multiple-rooted PMFPs were significantly associated with an increased prevalence of MB2 canals in PMFPs, even after adjusting for sex, age and side. This observation supports the concept that anatomical complexity in maxillary premolars may reflect corresponding variations in maxillary molars, offering a useful predictor for clinicians during endodontic treatment planning.

The prevalence of MB2 observed in this study aligns with earlier reports in Taiwanese populations, which have ranged between 45.9 % and 74.0 %.^{7,8} This variability may reflect differences in sample size, imaging technology, and classification systems. Our findings reinforce the importance of regional data, as ethnic and population-specific variations in root and canal anatomy are well established.⁶ Furthermore, males demonstrated a slightly higher prevalence of multi-rooted PMFPs and MB2 canals in PMFPs compared with females, which is consistent with previous observations of sexual dimorphism in Taiwanese root canal morphology,⁹ and western Asia population.¹³ However, age and tooth side showed no significant influence, suggesting

Table 2 The association between the variables and the presence of MB2 in PMFPs was analyzed using multivariable logistic regression.

	Adjusted OR	PMFPs		P-value
		95 % CI		
		Lower	Upper	
Sex				
Female	Referent			
Male	1.445	0.945	2.209	0.089
Age				
<50 years	Referent			
≥50 years	1.419	0.921	2.187	0.383
Side				
Right	Referent			
Left	1.282	0.842	1.952	0.223
PMFPs				
One root	Referent			
Multiple roots	2.081	1.336	3.242	0.001**

PMFPs, permanent maxillary first premolars; PMFPs, permanent maxillary first molars; MB2, second mesiobuccal canal; OR, odds ratio; CI, confidence interval. The level of statistical significance was set at $P < 0.05^*$, $P < 0.05^*$, $P < 0.01^{**}$, $P < 0.001^{***}$.

that these factors may play a limited role in determining canal complexity.

Vertucci's classification highlighted that PMFPs exhibited a broad spectrum of canal configurations, with Types I, III, IV, and II being most common in single-rooted teeth. Similarly, the mesiobuccal roots of PMFPs demonstrated notable complexity, with nearly one-third classified as Type IV. These findings emphasize the clinical challenge of locating and treating MB2 canals, which, if left undetected, are a well-documented cause of persistent apical periodontitis and endodontic failure.¹⁴ The strong bilateral symmetry observed in both PMFP root number (81.4 %) and PMFP MB2 occurrence (85.1 %) further suggests that contralateral teeth may serve as reliable references during diagnosis and treatment.

Table 3 Distribution of Vertucci’s classification of PMFPs’ and PMFMs’ canal configurations (n = 376).

Tooth type	Canal classification								Total
	Type I	Type II	Type III	Type IV	Type V	Type VI	Type VII	Type VIII	
PMFPs									
One root	55 (14.6)	39 (10.4)	54 (14.3)	51 (13.6)	27 (7.2)	2 (0.5)	1 (0.2)	0	229 (60.9)
Two roots	0	0	0	141 (37.5)	0	0	0	0	141 (37.5)
Three roots	0	0	0	0	0	0	0	6 (1.6)	6 (1.6)
PMFMs									
MB root	158 (42.0)	89 (23.6)	4 (1.0)	116 (30.8)	6 (1.6)	2 (0.5)	1 (0.2)	0	376 (100)

PMFPs, permanent maxillary first premolars; PMFMs, permanent maxillary first molars; MB, mesiobuccal.

Table 4 The correlation between the root number of the contralateral PMFPs and without/with MB2 in PMSPs was analyzed. (N = 188).

	PMFPs, right (N)				P-value
	One root	Two roots	Three roots	Total	
PMFPs, left (N)					
One root	97	20	0	117	<0.001***
Two roots	15	53	0	68	
Three roots	0	0	3	3	
Total	112	73	3	188	
	PMFMs, right (N)			P-value	
	Without MB2	With MB2	Total		
PMFMs, left (N)					
Without MB2	65	9	74	<0.001***	
With MB2	19	95	114		
Total	84	104	188		

PMFPs, permanent maxillary first premolars; PMFMs, permanent maxillary first molars; MB2, second mesiobuccal canal; N, number of patients. Data were analyzed using chi-square test. The level of statistical significance was set at $P < 0.05^*$, $P < 0.05^*$, $P < 0.01^{**}$, $P < 0.001^{***}$.

From a clinical perspective, these results hold practical value. Identifying multiple roots in PMFPs on a routine periapical radiograph may alert clinicians to a higher likelihood of MB2 canals in adjacent PMFMs. This insight can guide more meticulous exploration during access cavity preparation and may reduce reliance on CBCT, thereby minimizing radiation exposure in accordance with the ALARA principle. Nevertheless, CBCT remains invaluable in cases with persistent diagnostic uncertainty or complex anatomy.⁵

Several limitations should be acknowledged. First, although CBCT is highly accurate for detecting root canal morphology, it cannot compare with micro-CT, which remains the gold standard for anatomical studies.⁵ Second, this study was retrospective in nature and relied on images obtained for clinical rather than research purposes, which may have introduced selection bias.¹² Third, while our sample size was adequately powered, the findings are limited to a single Taiwanese cohort and may not be directly generalizable to other populations. Future investigations should consider multi-center studies with larger and more diverse samples, as well as subgroup

analyses incorporating demographic variables such as ethnicity, sex, and age. In addition, evaluating the impact of technological advances in CBCT resolution on diagnostic accuracy would be of interest.

In this study, multiple-rooted PMFPs were found to be significantly associated with an increased prevalence of MB2 canals in adjacent PMFMs. The strong bilateral symmetry observed in both PMFP root number and MB2 occurrence in PMFMs suggests that contralateral teeth may serve as reliable clinical references. These findings highlight the predictive value of PMFP root morphology in anticipating MB2 complexity, thereby supporting more accurate endodontic diagnosis and treatment planning. Routine periapical radiographs that reveal multiple roots in PMFPs may provide clinicians with a practical indicator of MB2 presence in PMFMs, potentially improving treatment outcomes as an alternative to CBCT scanning.

Declaration of competing interest

The authors have no conflicts of interest relevant to this article.

Acknowledgments

This research was funded by research grants from Tri-Service General Hospital, Taipei, Taiwan (TSGH-C106-133), (TSGH_C03_114037) and Ministry of Education, Taiwan (PMN1140414).

Appendix A. Supplementary data

Supplementary data to this article can be found online at <https://doi.org/10.1016/j.jds.2025.10.029>.

References

1. Gulabivala K, Ng YL. Factors that affect the outcomes of root canal treatment and retreatment—A reframing of the principles. *Int Endod J* 2023;56(Suppl 2):82–115.
2. Nair PR. Pathogenesis of apical periodontitis and the causes of endodontic failures. *Crit Rev Oral Biol Med* 2004;15:348–81.
3. Costa F, Pacheco-Yanes J, Siqueira Jr JF, et al. Association between missed canals and apical periodontitis. *Int Endod J* 2019;52:400–6.
4. Estrela C, Holland R, Estrela CRdA, Alencar AHG, Sousa-Neto MD, Pécora JD. Characterization of successful root canal treatment. *Braz Dent J* 2014;25:3–11.
5. Wu YC, Chiang HS, Dai ZJ, et al. Top 100 most-cited articles in root canal anatomy: a Scopus-based bibliometric study. *J Endod* (in press).
6. Martins JNR, Alkhawas MAM, Altaki Z, et al. Worldwide analyses of maxillary first molar second mesiobuccal prevalence: a multicenter cone-beam computed tomographic study. *J Endod* 2018;44:1641–9.
7. Tzeng LT, Chang MC, Chang SH, Huang CC, Chen YJ, Jeng JH. Analysis of root canal system of maxillary first and second molars and their correlations by cone beam computed tomography. *J Formos Med Assoc* 2020;119:968–73.
8. Su CC, Huang RY, Wu YC, et al. Detection and location of second mesiobuccal canal in permanent maxillary teeth: a cone-beam computed tomography analysis in a Taiwanese population. *Arch Oral Biol* 2019;98:108–14.
9. Wu JY, Chiang HS, Chen YJ, et al. Prevalence of second mesiobuccal canal in maxillary first and second molar detected using cone-beam computed tomography in the Han population: a systemic review and meta-analysis. *J Dent Sci* (in press).
10. Tian YY, Guo B, Zhang R, et al. Root and canal morphology of maxillary first premolars in a Chinese subpopulation evaluated using cone-beam computed tomography. *Int Endod J* 2012;45:996–1003.
11. Landis JR, Koch GG. An application of hierarchical Kappa-type statistics in the assessment of majority agreement among multiple observers. *Biometrics* 1977;33:363–74.
12. Wu YC, Su CC, Tsai YC, et al. Complicated root canal configuration of mandibular first premolars is correlated with the presence of the distolingual root in mandibular first molars: a cone-beam computed tomographic study in Taiwanese individuals. *J Endod* 2017;43:1064–71.
13. Qamar Z, Almohana SA, Almohana AA, et al. Mandibular premolars endodontic anatomy and role in sex dimorphism for Western Asia population using CBCT 3D imaging technique. *Int J Morphol* 2021;39:6.
14. Baruwa AO, Martins JNR, Meirinhos J, et al. The influence of missed canals on the prevalence of periapical lesions in endodontically treated teeth: a cross-sectional study. *J Endod* 2020;46:34–9.